

Transcranial magnetic stimulation versus electroconvulsive shocks – neuroanatomical investigations in rats *

Tomasz Zys^{1,2}, Dariusz Adamek³, Andrzej Zięba²,
Jerzy Vetulani⁴, Jacek Mamczarz⁴, Joanna Mika⁴, Adam Roman⁴

¹ EEG and EP Laboratory, Department of Neurology, University Hospital, Cracow

² Department of Psychiatry, Collegium Medicum, Jagellonian University, Cracow

³ Neuropathology Unit, Department of Neurology,

Collegium Medicum, Jagellonian University, Cracow

⁴ Institute of Pharmacology, Polish Academy of Sciences, Cracow

Since the time of introducing ECT to the clinical practice, the method always raised questions regarding possibility that the current running through structures of a brain may evoke structural changes and as a result of these evoke convulsive attacks. Pathological changes (swelling, gliosis, atrophy, necrosis) were observed most often after “mega”-schemes including series of several to several hundreds ECT treatments. Regime used nowadays including only 8-12 ECT sessions seems to be entirely safe. There are however only a few experimental works dealing with this problem.

In 1992 researches started on new neurophysiological technique - transcranial magnetic stimulation (TMS) in depression. The advantage of this method is that it does not seem to evoke convulsive attacks. Prolonged rapid rate TMS (rTMS) seems to be particularly efficient in treatment of depression. Despite thousands of works describing various functional effects of TMS, there are obviously no researches on structural effects of the technique. In the case of experimental researches on animals a few works were published and their results seems to be ambiguous.

We have examined the influence of prolonged repetitive rTMS ($B = 1.4 T$, $t = 5.5 \text{ min}$, $f = 30 \text{ Hz}$), and standard ECT ($I = 150 \text{ mA}$, $t = 0.5 \text{ s}$, $f = 50 \text{ Hz}$) on the structure of brain tissue in rats. Both groups of animals ($n=10$) received 12 stimulation sessions. After the treatment the animals were routinely processed for electron microscopy (EM) and for light microscopy (LM).

The microscopy light - did not show, ECT or rTMS to evoke structural changes in brain stimulated of animals – in comparison with the control group. Differences between both groups succeeded to obtain only by electron microscopy technique. In brains of animals that underwent ECT were found numerous and considerably edematous and degenerative changes. Brains of animals that underwent rTMS showed existence only of small edematous changes, whose intensity was significantly less than in at animals after ECT.

Our investigations suggest that the technique of ECT shows considerable neurotoxic potential. In comparison to ECT - the rTMS method seems to be more safe.

Key words: electroconvulsive shocks, transcranial magnetic stimulation, neuropathological investigation, rat

* This work was supported by KBN grant 4 P05B 038 18.

Introduction

In 1998 it was exactly 60 years since the first epileptic attack in a patient with psychosis was evoked with electric current in a Roman Psychiatric Hospital treating psychotic patients [1]. Literature provides proofs that even much earlier physicians tried to make use of, e.g., electric fish discharges or, a little later, of a Leyden jar (precursor of a condenser) in treatment of mental disorders. However, it is Cerletti and Bini, who are recognised as authors of modern seismic therapy. At present, electroconvulsive therapy (ECT) is one of the numerous and highly varied shock methods (cardiasoleand and pentatrasole shocks, insulin and atropin comas), which not only survived to our time, but is also considered as an exceptionally effective method [cit. after 2]. Initially, ECT was applied very extensively: in psychoses, depression or even in neurotic syndromes. With the development of pharmacotherapy the areas of ECT application were strongly limited, and now it is used only in the cases of severe endogenous depressive syndromes. Despite its' high effectiveness (estimated as higher than that of antidepressant drugs) and the proved cellular action mechanisms (tissue receptors, neurotransmitter systems, ionic channels) – similar, to a certain extent, to the action of antidepressant drugs – ECT is recognised as the second choice method. This situation is caused not only by the complicated procedure of electroconvulsive therapy (short-time anaesthesia, muscle relaxation, oxygen ventilation), but also by the complex equipment (ECT apparatus, anaesthetic equipment).

The basic difficulties in extensive application of ECT seem to issue from doubts of moral and ethical character that are still evoked by this therapy. Electroshock seems to be a word horrible enough not only for patients but also for a large part of the medical personnel. To diminish the odium, doctors often use the abbreviation ECT as the name of this method; in some countries, names like electro-narcosis, electro-sleep, electro-plexion or electro-stimulation are also used. The ECT method was described as a “barbarian anachronism”, “penal shock”, “annihilation method”, or “the method destroying the patient’s brain and personality”, and since that time many a man considers it a symbol of inhumane and restrictive psychiatry [3]. For a non-professional it seems savage, since it consists in sending electric current through the skull and brain, and the public opinion most frequently associates application of ECT with repression, backwardness and helplessness of psychiatric treatment.

Fear of ECT is connected with the fear of evoking permanent changes in brain tissue [14, 24] with all clinical, behavioural and emotional consequences of this situation. Literature dealing with neuro-anatomic effects of ECT is rich, and discusses both clinical investigations and experiments on animals [6, 7, 8, 9, 10, 11]. The results reveal great discrepancies regarding the occurrence of neuro-structural changes after ECT administration, or their lack. This is why we started our own neuro-histopathological investigations on structural effects of ECT series administered to rats. The results were compared with those obtained in animals submitted to a prolonged transcranial magnetic stimulation – a new neuro-physiological method considered as antidepressant.

Electroshocks and non-convulsive electric stimulation in animals

The authors of ECT – Cerletti and Bini – were the first to conduct experiments on animals, which were aimed to confirm safety of the method [12]. Administering series of electroshocks to dogs, they proved that even 40 operations of this kind did not evoke specific changes in the central nervous system. Changes in brain cells of dogs occurred as late as after 70 operation repeated at short intervals. The changes were of oedematous character.

In the subsequent years, investigations of neuroanatomical effects were continued with the use of various electric current parameters (frequency, intensity, stimulation time) applied to different species of mammals, primates included. In his monograph, Krzyżowski presents a survey of anatomico-pathological changes observed in the older experimental studies [2]. They have been listed in table 1.

Table 1
Neuroanatomical changes observed in animals after electroshocks [modified after 2]

AUTHORS	ANIMAL	METHOD	RESULTS
Cerletti U, Bini L; 1938	dog	40 treatments 70 treatments	no changes swelling
Heilbrunn G, Liebert E; 1941	rabbit		no changes
Alperin E.J, Hughes J; 1942	cat		vascular changes small punctual ecchymoses
Echlin F.A; 1942	dog		hypoxia swelling vasospasms
Hadenbrock S, Ewald G; 1942	monkey		no changes
Heilbrunn G, Weil A; 1942			no changes
Neuburger K.T, Whithead R.U., Rutledge E.K, Ebaugh F.G; 1942	dog		neuron atrophy vascular changes
Globus J.H, van Harnveld A, Olkema C.A; 1943	dog	30 s (1), 200-700 mA	no changes
Alexander L, Löwenbach F; 1944	cat	500- 1800 mA = 200 mA	narrowing of light of vessels dilating of light of vessels
Lindbeck U.L; 1944	dog	multiple ECT	ischemic changes
Uinkelman N.U, Moore M.T; 1944	cat		no changes
Ferraro A, Roizen L, Holland M; 1945	monkey		hypoxia swelling
Kreienberg U, Ehrhard U; 1947			narrowing of light of vessels

Siebert R.G., Williams S.C., Uinde U.F.; 1960	monkey		no changes
Hartelius H; 1962			no changes
Ugher J, Winescu S, Wolanski G, Stiva J; 1968	dog		atrophy
Milbert E, Baumgartner G, Kettner U.P.; 1967	cat		neuronal changes, nucleus damage, cellular membranes degeneration, mitochondrial damage
Hartelius G; 1968	rat		hippocampus atrophy
Sommer H; 1971			no changes
Lippman S; 1985			no changes

More recently, fewer studies have been conducted on macro-structural effects of ECT. In the 1970s and 1980s research was made on the influence of acute and prolonged electric stimulation of the central nervous system tissue (brain, cerebellum and spinal cord) with the current not evoking convulsive attacks [13, 14, 15, 16, 17, 18]. These investigations were conducted, i.a., to provide an answer to the question concerning safety of the newly introduced methods of treatment of some neurological disorders. In treatment of disorders like epilepsy, dystonia or some chronic pain syndromes, doctors tried to use electric stimulation with electrodes implanted in the central nervous system and connected with an external miniature stimulator. The described method has not been widely applied in clinical conditions, mostly due to definite technical problems (foreign body in the organism meant an open door for infection) and to objections of ethical and moral character. Threats connected with possible structural injury to nerve cells resulting from electric current flow were mentioned on further places (table 2).

Single electric impulses were used at the beginning of the 1980s to examine the

Table 2
Neuroanatomical changes observed in animals after non-convulsive electrical stimulation

AUTHORS	ANIMAL	RESULTS
Agnew U.A. et al.; 1975	cat	from light to heavy ultrastructural cellular damage
Rudenz R.H. et al.; 1975	cat	reversible (after 1 week) damage of blood-brain-barrier
Brown U.J. et al.; 1977	monkey	pachymeningeal thickness, Purkinje cells damage, glial cells expansion, axonal degeneration, collagen intercellular, polysaccharide aggregation
Agnew U.F. et al.; 1983	cat	no changes
Agnew U.F. et al.; 1985	cat	little cellular and vascular

so-called evoked motor potentials. This technique was a precursor of the method of transcranial magnetic stimulation described below. However, due to its significant level of painfulness it was not widely applied in clinical practice. Experiments on animals performed with this method revealed that electric stimulation evoked structural changes not only within nerve tissue of the brain but also in the meninges and soft tissues of the head. In their character, these changes were injuries to blood vessels with subsequent extravasations and haemorrhagic changes [19, 20]. However, the currents used in this method were of a relatively high tension – exceeding 1000 Volt.

Electroconvulsive therapy in people

As we have already mentioned in the introduction, fear of potential brain damage was probably the most important factor causing unfavourable connotation of ECT technique. The bias against ECT was based mostly on the results of experiments on animals. It is thus understandable that the possibility of conducting neurostructural investigations in hospital conditions was limited. More than half a century of administration of ECT to persons with various mental disorders had provided a large number of death cases of patients who died in the period of electroconvulsive therapy or shortly afterwards. Literature also reports cases of patients who died during or directly after ECT administration. Table 3 presents neuroanatomical data collected in patients subjected to ECT [cit. after 2]. The observed macro- and microscopic changes were of non-specific character. Some of these changes might be connected with the patients' old age. However, the relation between the detected structural changes and the ECT operation itself remains an open question [21, 22]. Some authors detected similar changes in cells and on sub-cell level in patients with epilepsy [23].

The development of medical technology in recent decades brought about the pos-

Table 3

Casuistic papers about anatomopathological changes in patients after ECT
[modified after 2].

AUTHORS	PATIENT AGE	NUMBER OF TREATMENTS	TIME BETWEEN THE LAST TREATMENT AND DEATH	RESULTS
Alpers B.J., Hughes J; 1942	45	46	2 months	punctal hemorrhage in cortex, medulla and cerebellum
	79	6	5 months	arteriosclerosis, congestion, cellular and fibrous gliosis
Cash, Hoderick	47	5	2 hours 10 min	no changes
Clute	59	1	7 days	arteriosclerosis

Cornelius, Meyer	21	6	Immediately after	perivascular changes, periventricular and perivascular gliosis
	4	45	Immediately after	little perivascular hemorrhages, astrocytes and fibrous gliosis
Guochi	6	3	4 min	arteriole rosis, diffuse subarachnoid ecchymoses
Ebang	51	13	35 min	diffuse degeneration, astrocytic gliosis
	51	3	Immediately after	neurosis in cortex, hippocampus and medulla, astrocytes and fibrous gliosis
Gayle, Neale	-	-	-	cyt. in IV ventricle
Goodman	21	3	3 days	swelling, endothelial changes, diffuse gliosis
Gralnick A., 1944	35	2	2 days	swelling and hyperemia, vascular syphilis
	6	2	3 days	arteriole rosis, big fibroblastoma
Jellier	41	4	12 min	arteriole rosis
	1	6	12 min	arteriole rosis
Larsen, Uraev-Jensen	4	4	34 hours	swelling and small hemorrhages in subependymal areas, neuronal thinning in frontal lobes, gliosis
Meadey	5	3	20 min	thrombosis
	4	2	2 hours	intracerebral hemorrhages
	51	1	50 min	little hemorrhages into pons and medulla prolongata
	2	2	Immediately after	swelling in mesencephalon, temporal and parietal lobes
	52	2	Immediately after	little hemorrhages into wall of IV ventricle and medulla prolongata
Miklow L., 1954	34	1	Immediately after	little perivascular hemorrhages

Marlin B.A.; 1986	47	6	9 days	little hemorrhage
	40	4	15 days	little hemorrhage
	52	11	12 days	arteriosclerosis
	52	8	24 days	little hemorrhage
Mediso tt	54	1	some weeks	cerebral hemorrhage
Meyer, Teare	53	1	12 hours	infarct in cerebrum and cerebellum
Napier	46	1	6 hours	-
	62	2	40 min.	cortical atrophy
Rene	30	2	48 hours	swelling, hemorrhage in the medulla oblongata, typhoid
	55	2	10 min	arteriosclerosis, little hemorrhages, degenerating gliosis
Spence, Taylor	48	6	12 days	hemorrhage into the left temporal lobe and hippocampus
Solomon	20	19	15 hours	-
Uhl, et al.	48	1	20 min	acute brain swelling, central chromatolysis
Uban E, Halpem A, Róganska N; 1951	47	7	7 days	diffuse subarachnoidal ecchymoses, sinus thrombosis, swelling
Levy	-	-	-	vascular dilatation with hyperemia

Coffey C. E et al.; 1991	35 patients	MRI before, immediately after and 6 months after ECT	no signs of structural CNS damage
--------------------------	-------------	--	-----------------------------------

sibility of evaluation of macroscopic brain structure in vivo. Neuroimaging methods like computed tomography (CT) or magnetic resonance imaging (MRI) allow for structural investigations with a fraction of millimetre accuracy. The above mentioned techniques have been used to assess the results of ECT. In 1991, Coffey's group examined 35 patients subjected to ECT [24]. With the use of MRI they did not detect the occurrence of any structural changes – either directly after ECT administration or 6 months afterwards.

To what extent the results of clinical investigation results may differ is shown in the report by Shah et al. of 1998 [25]. MRI examinations conducted in 20 patients with depression revealed the existence of cortical atrophy limited to the left temporal lobe and both hippocamps (particularly to the left one). The examinations covered patients with the diagnosis of drug resistant major depression, and some of the pa-

tients had been subjected to at least 6 ECT operations. However, the authors were not able to state whether the detected neurostructural changes were connected with the primarily chronic disorder (i.e., depression itself) or were the result of its treatment (pharmacotherapy and/or ECT). Some other authors also admitted similar ignorance [26, 27]. Others, in turn, claim that brain atrophy detected in patients with depression is a direct result of the applied ECT or prolonged pharmacotherapy [28, 29, 30, 31]. A number of authors associate the intensity of structural changes with the parameters of the applied electric current [32].

Transcranial magnetic stimulation

In 1985, a new neurophysiological method consisting in application of a strong impulsive magnetic field to the patient's head was introduced in neurological diagnostics [after 33]. This techniques, called transcranial magnetic stimulation (TMS) proved to be an exceptionally valuable instrument in studies on speech, memory, sight, hearing and motor systems. In the recent years we have witnessed attempts at application of this method for therapeutic aims: in depression, Parkinson's disease, multiple sclerosis and pain syndromes. The first author of this work suggested application of TMS technique in treatment of depression as early as 1992 [33]. Till today, ca. 150 patients with depression have been subjected to magnetic stimulation procedure all over the world. Several reports have been published of clinical studies conducted according to the procedure of third phase examinations of chemical substances (drugs) of antidepressant character. The obtained results clearly confirm the antidepressant effect of TMS technique [34, 35, 36].

The great interest in TMS technique issues from its high safety level. In contrast to the hitherto applied methods of electric stimulation, the examined person remains beyond the electric system of the stimulator. Magnetic stimulation itself is not painful, unpleasant or burdening for a healthy person (diagnostic examinations) or for a patient (therapy).

We must not forget, however, that TMS consists in direct application to the examined person's head of a strong magnetic field whose induction might sometimes amount to 3 Tesla. Hence, despite the significant safety of the TMS technique, we must not forget about some possible dangers or risk connected with it. The description of undesired side effects of TMS is beyond the frames of this work. So far, no death case of a person subjected to TMS has been described, hence we have no autopsy data comparable to those collected from persons subject to ECT. Neither do we know of any clinical studies with the use of CT or MRI techniques that would confirm macrostructural changes evoked by transcranial magnetic stimulation (TMS). On the other hand, there are several studies in which experimental animals were subjected to TMS [37, 38, 39, 40, 41, 42]. The results of these studies are collected in table 4; they show that it was only the Japanese group that managed to detect structural changes in ca 50% of the rats subjected to TMS [38, 39].

In turn, Prato et al. [43] detected the blood-brain barrier damage in animals submit-

Table 4

**Neurostructural changes observed in animals
after non-convulsive transcranial magnetic stimulation**

AUTHORS	ANIMAL	METHOD	RESULTS
Ramborg M, Knudsen G.M, Blinkenberg M; 1990	30 rats	B = 1,9 T, 50-60 impulses, 1 series	no influence on permeability of blood-brain barrier
Sgro J.A, Ghatak N.R, Stanton P.C, Emerson R.G, Blair R; 1991	31 rats	B = 3,4 T, 8 Hz, 10,000 impulses in 20 min	no changes
Matsumiya Y, Yamamoto T, Yasuda M, Miyuchi S, Ning J.C.; 1992	25 rats	B = 2,8 T, 100-5381 impulses, 1 series	microvascular changes in neuropil of cortical layers 2-6 in 50% of animals
Cramer S.A; 1993	16 rabbits	B = 2 T, 1000 imp, 100 imp. / treatment, 4-12 months of stimulation	microscope: normal structure, no changes of damage; MRI: no macrostructural changes

ted to the action of a strong constant magnetic field generated by a MRI scanner.

Aim of the work

The aim of this work was to evaluate the influence of repeated transcranial magnetic stimulation and electroshocks in rats on the possible occurrence of structural changes in their central nervous system.

Material and method

The examinations were performed on 30 male Wistar rats weighing 200-300 g, kept 5 animals per cage in standard conditions (environment temperature 22-23°C; 12 hours cycle of light and dark phases; food and water ad lib.).

A group of 10 rats was subjected to magnetic stimulation with the use of a prototypical magnetic stimulator MS 3, constructed in collaboration with the Electro-technology Institute in Warsaw (Andrzej Pawlaczyk, DSc; Andrzej Domino, MSc); Experimental Unit of Research Equipment and Automatics of the Academy of Mining and Metallurgy (Jacek Seńkowski, DSc, Paweł Kwasnowski, MSc) and Electro-mechanics Department in Cracow (Stanisław and Dariusz Gierlik). During the experiments, the stimulator produced an impulsive magnetic field of induction $B = 1.4$ T and frequency $f = 30$ Hz. The time of field increase was 120 μ s. Total time of one series of magnetic stimulation was 5 min and 30 s (corresponding to 10,000 impulses of magnetic field). The animals were subjected to 12 stimulations (one operation a day) executed in midday period every second day.

Another group consisted of 10 rats subjected to electroshocks applied with ear-

electrodes (clips). The ECT apparatus ZK-2 generated electric current of the following parameters: $I = 150 \text{ mA}$; $t = 0.5 \text{ s}$; $f = 50 \text{ Hz}$. Overall, the animals received a series of 12 ECT operations according to a schedule similar to that of TMS.

The remaining ten animals constituted a control group.

The animals were anaesthetised with Venbutal narcosis (100mg/kg) 24-48 hours after the last stimulation. Then, for 4,5 hours they were perfused with a solution of buffered formalin (for light microscopy) or with Karnofsky's fixative (for electron microscopy). After the perfusion, the acquired brains were additionally fixed in the same solutions as those used for perfusion. The brains fixed in this way were submitted to neuropathological examination.

The fixed animal brains for light microscopy examination were selected in the plane perpendicular to the longitudinal axis of brain, dividing them into 5 cross-sections of equal thickness, which were then transferred in a standard way to paraffin blocks, and cut. The fragments were stained with the following methods: hematoxylin-eosin, Klüver-Barrér's method and PAS. Besides, fragments were stained immunohistochemically with the use of cow antibodies against GFAP (glial fibrillary acid protein – astrocyte marker) in a 1:100 titre with 24 hour incubation. For immunohistochemical examination we used primary antibody and the remaining re-agents produced by DAKO.

For electron microscopy we used samples of brain tissue taken from the following areas: frontal and temporal cortex, lenticular and caudate nucleus, thalamus, cerebellum, medulla oblongata and corpus callosum. The fixed tissue samples were rinsed four times in 7% saccharose solution, then osmosed for 2 hours, transferred to a standard Spurr type polymer, and cut. Ultrathin fragments placed on copper net trays were fixed and stained with uranylacetate and lead citrate (Vanable's re-agents). Preparations were examined with ZEISS EM 900 microscope. At the moment of examination, the pathomorphologist (D.A.) did not know the group assignation (control, ECT, TMS) of animals from which the examined samples were taken.

Results and discussion

Table 5 presents the complete set of examination results.

Examinations in light microscopy (LM) did not detect any pathological changes in the groups of animals subjected to ECT or to TMS. This regarded both histological methods and GFAP expression preservation. Microphotograph 1a represents the hippocampus area of the rat subjected to ECT. The histological picture does not differ from normal. Also, immunohistochemical expression of GFAP was similar in all three groups of animals. Microphotographs 1b and 1c represent samples of cortex of rats after ECT and TMS respectively. GFAP-positive delicate fibrillar astrocytes, like those in both photographs, did not differ from control cases either as regards their number or intensity of expression. Glial fibrillary acid protein (GFAP) produced by astrocytes and especially by reactively "agitated" astrocytes, is recognized as a neurotoxicity marker [44], and its increased expression accompanies, i.a., ischaemic changes [45]. What is particularly interesting for our studies – experiments with ECT in mice revealed an increase of mRNA for GFAP [46]. Fujiki and Steward also detected an increased mRNA expression for GFAP in mice stimulated with TMS [47]. Also, a transitory,

Table 5

**Neuropathological changes in rat brains which underwent electroshocks
and transcranial magnetic stimulation**

TRANSCRANIAL MAGNETIC STIMULATION TMS	ELECTROCONVULSIVE SHOCKS ECT
<i>light microscopy LM:</i>	
no changes	no changes
<i>electron microscopy EM:</i>	
THALAMUS AND CEREBELLUM vascularization of pericapillary glial cell (less than after ECT)	CORPUS CALLOSUM: extracellular edema PARIETAL CORTEX: lipofuscin aggregates THALAMUS AND CEREBELLUM: significant vascularization of glial cell especially around capillaries SEVERAL REGIONS OF BRAIN: ballooned mitochondrial cristae

short-time GFAP increase in glia-cell culture subjected to magnetic stimulation has been reported recently [48]. Statistically significant increase of GFAP in cells occurred three days after stimulation, but it came back to normal on the fifth day. However, the above mentioned authors not only applied a different model of experiment (cell culture and a single ten-second stimulation), but also evaluated GFAP expression in a different way (the so-called immunoblot). It is worth emphasizing that no morphological changes of glia were detected after magnetic stimulation, and therefore the lack of morphologically noticeable increase of GFAP expression in our experiment need not contradict the above mentioned report. Our results indicate only that probably a long-time reaction of glia to TMS does not occur, which is in accord with observations reported by Chan et al. [48].

Taking into account the strict relation between astrocytes and neurons (for which astrocytes perform, i.a., protective functions in the process of excitotoxicity), the existing data may allow for formulation of the hypothesis that TMS, through a delicate modulation of astrocyte activity, can improve the functioning of neurons [49].

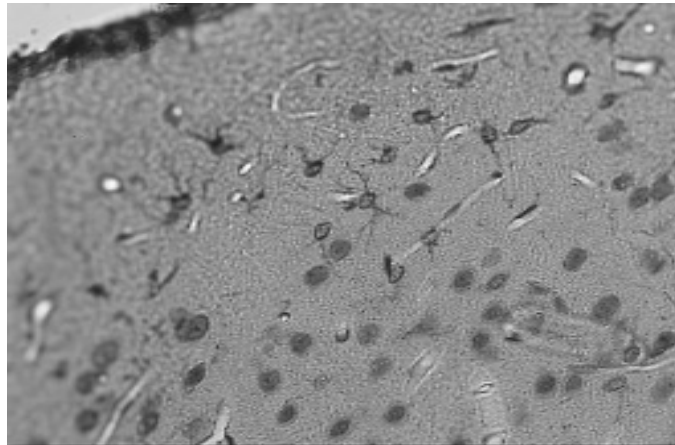
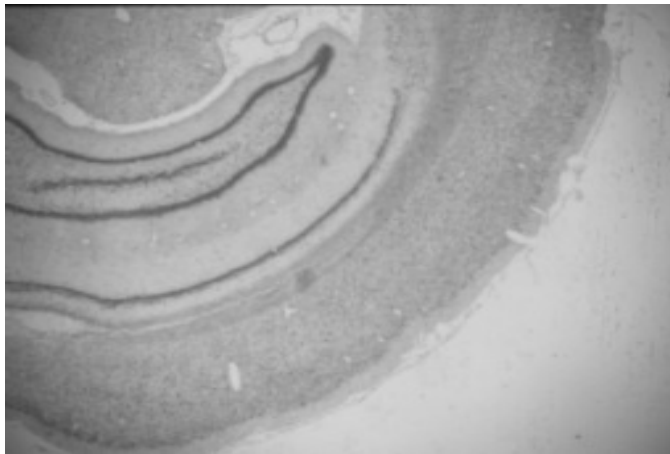
In the ultrastructural examinations (electron microscope), we detected pathological changes of moderate intensity in the group subjected to ECT, and of slight intensity in the group subjected to TMS. These changes, assuming the form of oedemic dilatation of extracellular space, occurred mostly in corpus callosum of rats after ECT (photo 2b). Both in the group after ECT and that after TMS we detected distention

and vacuolar changes of processes of the perivascular glial cells, but in the group after ECT they were distinct (photo 3) while in the group after TMS they were very slight. Oedema of astrocytes or of their processes is typical of early ischaemic changes [45, 50], and is sometimes observed as a result of action of neurotoxic factors [51]. The slight oedema of mitochondria (and especially of crests) detected in the brains after ECT (photo 4), though hardly marked, may also be connected with hypoxia [52] and/or with free radicals activity [53].

Conclusion

The obtained results suggest that electroconvulsive therapy – despite its recognised

Photo 1. Structure of rat brains after ECT and TMS in light microscopy: a) hippocampus after ECT (Klüver-Barrér, ocular: 2x); b) frontal cortex after ECT (GFAP; ocular: 40x); c) parietal after TMS (GFAP; ocular: 40x).



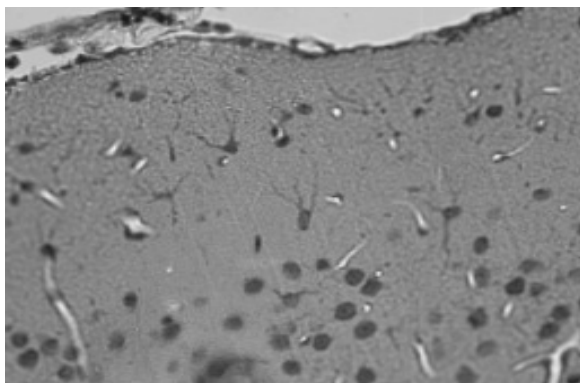


Photo 2. Corpus callosum: normal structure in rats after rTMS (a) and slightly extacellular edema () in animals after ECS (b); = 1 μ m

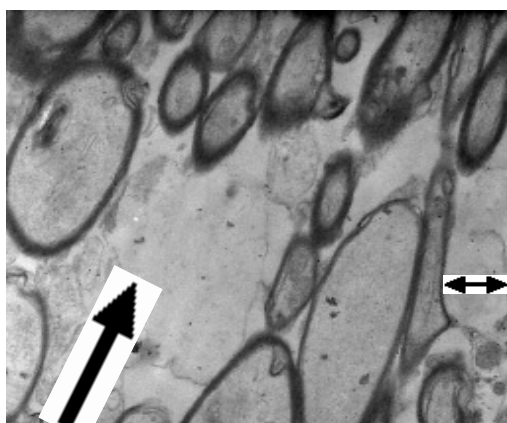
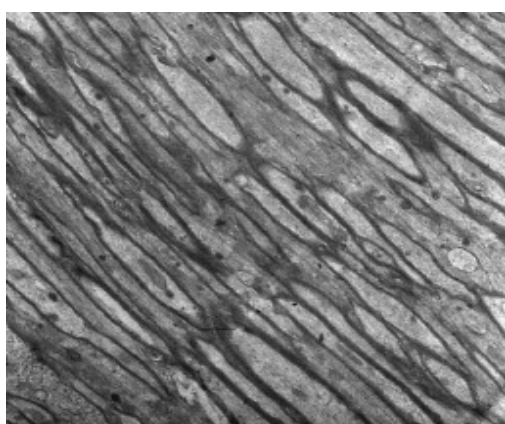


Photo 3. **Thalamus: vacuolization of glial cell especially around capillries (↑)**
in rats after ECS; $\leftrightarrow = 1 \mu\text{m}$

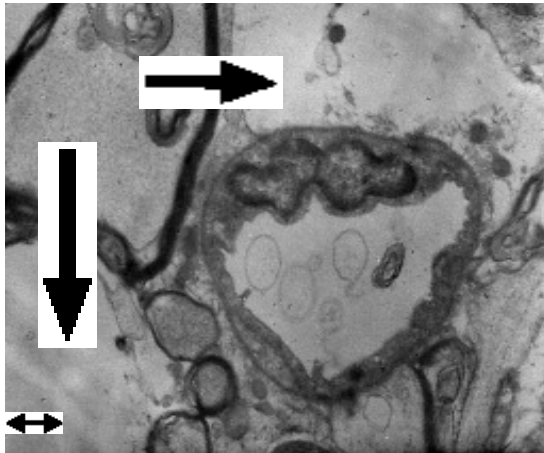
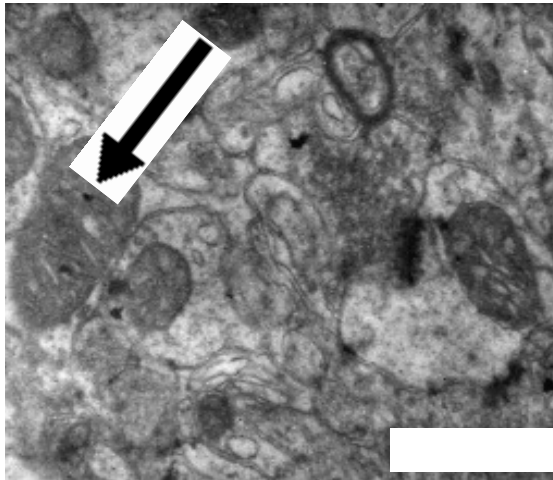


Photo 4. **Little ballooned swelling of mitochondrial cristae (↑)**
in rats after ECS; powiększenie: $\leftrightarrow = 1 \mu\text{m}$



high clinical effectiveness – is characterized by a neurotoxic potential. Neurostructural changes evoked by ECT could be detected only in electron microscopy and were of oedemic or degenerative character. On the other hand, oedemic changes observed after TMS were of moderate intensity – they never amounted to the intensity observed after ECT. Therefore, TMS technique seems safer than the corresponding electric method in the form of ECT.

Literature

1. Cerletti U, Bini L: *L'elettroshock*. Arch. Gen. Neurol. Psychiat. 1938, 19: 266-2. Krzyżowski J: *Zmiany anatomopatologiczne w czasie kuracji elektrowstrząsowej*. In: Krzyżowski J (red.): *Leczenie elektrowstrząsowe*. LogoScript, Warszawa 1991: 61-70.
3. Kesey K: *Lot nad kukulczym gniazdem*. Da Capo, Warszawa 1993.
4. Devanand DP, Dwork AJ, Hutchinson ER, Bolwig TG, Sackeim HA: *Does ECT alter brain structure?* Am. J. Psychiatry 1994, 151: 957-970.
5. Kendell B, Pratt RT: *Brain damage and ECT* (letter). Br. J. Psychiatry 1983, 143: 99-100.
6. Fink M: *Risks of convulsive therapy and Anatomic data*. In: Fink M (ed.): *Convulsive therapy – theory and practice*. Raven Press, New York 1985: 41-50 and 178-180.
7. Heidrich R, Klagge E, Koch K, Leder H: *Einwirkungen elektrischer Reizspannungen auf das Gehirn. Eine tierexperimentelle Studie*. Psychiat. Neurol. med. Psychol. 1973, 25: 712-725.
8. Ingvar M: *Cerebral blood flow and metabolic rate during seizures. Relationship to epileptic brain damage*. W: Malitz S, Sackeim HA (ed.): *Electroconvulsive therapy – clinical and basic research issues*. Annals of the NYAS. Vol. 462. New York 1986: 194-206.
9. Maletzky BM: *Adverse effects III. Irreversible adverse effects. A. Brain damage*. In: Maletzky BM (ed.): *Multiple-monitored electroconvulsive therapy*. CRC Press, Boca Raton, Florida 1989: 179-182.
10. Martin BA, Jacobsen PM: *Electroconvulsive therapy and brain damage, the Ontario Supreme Court hearing of the evidence*. Can. J. Psychiatry 1986, 31: 381-386.
11. Scott AIF, Devanand DP, Sackeim HA: *Does ECT alter brain structure?* (letter). Am. J. Psychiatry 1995, 152: 1403.
12. Cerletti U, Bini L: *L'elettroshock. Le alterazioni istopatologiche del sistema nervoso in seguito all'E.S.* Riv. sper. Freniat. 1940, 64: 311-.
13. Agnew WF, Yuen TGH, McCreery DB: *Morphologic changes after prolonged electrical stimulation of the cat's cortex at defined charge densities*. Exp. Neurology 1983, 79: 397-411.
14. Agnew WF, Yuen TGH, McCreery DB, Bullara LA: *Histopathological evaluation of prolonged intracortical electrical stimulation*. Exp. Neurology 1986, 92: 161-185.
15. Agnew WF, Yuen TGH, Pudenz RH, Bullara LA: *Electrical stimulation of the brain. IV. Ultrastructural studies*. Surg. Neurol. 1975, 4: 438-448.
16. Brown WJ, Babb TL, Soper HV, Lieb JP, Ottino CA, Crandall PH: *Tissue reactions to long-term electrical stimulation of the cerebellum in monkeys*. J. Neurosurg. 1977, 47: 366-379.
17. Pudenz RH, Bullara LA, Dru D, Talalla A: *Electrical stimulation of the brain. II. Effects on the blood-brain barrier*. Surg. Neurol. 1975, 4: 265-270.
18. Pudenz RH, Bullara LA, Jacques S, Hambrecht FT: *Electrical stimulation of the brain. III. The neural damage model*. Surg. Neurol. 1975, 4: 389-400.
19. Sanscesario G, Massa R, Petrillo S, Nottola SA, Giacomini P, Correr S: *Transcranial unifocal stimulation, problems in localizing structural alteration on rabbit brain*. In: Rossini PM, Marsden CD (ed.): *Non-invasive stimulation of brain and spinal cord, fundamentals and clinical applications*. Neurology and Neurobiology Vol. 41. Allan R. Liss, New York 1988: 163-168.
20. Sanscesario G, Massa R, Petrillo S, Nottola SA, Giacomini P, Correr S, Rossini PM: *Transcranial unifocal stimulation in rabbit, subcutaneous and meningeal changes*. Eur. Neurol. 1989, 29: 93-98.
21. Meldrum BS: *Neuropathological consequences of chemically and electrically induced seizures*. In: Malitz S, Sackeim HA (ed.) *Electroconvulsive therapy – clinical and basic research issues*. Annals of the NYAS. Vol. 462. New York 1986: 186-193.
22. Menken M, Safer J, Goldfarb C, Varga E: *Multiple ECT, morphological effects*. Am. J. Psychiatry 1979, 136: 453.

23. Siejsö BK, Ingvar M, Wieloch T: *Cellular and molecular events underlying epileptic brain damages*. In: Malitz S, Sackeim HA (ed.): *Electroconvulsive therapy – clinical and basic research issues*. Annals of the NYAS. Vol. 462. New York 1986: 207-223.
24. Coffey CE: *The role of structural brain imaging in ECT*. Psychopharmacol. Bull. 1994, 30: 477-483.
25. Shah PJ, Ebmeier KP, Glabus MF, Goodwin GM: *Cortical grey matter reduction associated with treatment-resistant chronic unipolar depression*. Brit. J. Psychiatry 1998, 172: 527-532.
26. Altshuler LL: *Bipolar disorder, are repeated episodes associated with neuroanatomic and cognitive changes?* Bipolar Psychiatry 1993, 33: 563-565.
27. Puri BK, Oatridge A, Saeed N, Ging JE, McKee HM, Lekh SK, et al.: *Does electroconvulsive therapy lead to changes in cerebral structure* (letter). Br. J. Psychiatry 1998, 173: 267.
28. Calloway SP, Dolan R: *ECT and cerebral damage* (letter). Br. J. Psychiatry 1982, 140: 103.
29. Calloway SP, Dolan RJ, Jacoby RJ, Levy R: *ECT and cerebral atrophy. A computer tomographic study*. Acta Psychiatr. Scand. 1981, 64: 442-445.
30. Coffey CE, Weiner RD, Djang WT, Figiel GS, Soady SAR, Patterson LJ, et al.: *Brain anatomic effects of electroconvulsive therapy. A prospective magnetic resonance imaging study*. Arch. Gen. Psychiatry 1991, 48: 1013-1021.
31. Friedberg J: *Neuropathologic effects of ECT* (letter). Am. J. Psychiatry 1981, 138: 1129.
32. Gordon B, Lesser RP, Rance NE, Hart JJr, Webber R, Uematsu S, et al.: *Parameters for direct cortical electrical stimulation in the human, histopathologic confirmation*. EEG Clin. Neurophysiol. 1990, 75: 371-377.
33. Zyss T: *Czy terapia elektrowstrząsowa musi być „wstrząsowa” – hipoteza stymulacji magnetycznej mózgu jako nowej terapii psychiatrycznej*. Psychiatr. Pol. 1992, 6: 531-541.
34. George MS, Wassermann EM, Kimbrell TA, Little HJT, Williams WE, Danielson AL, et al.: *Mood improvement following daily left prefrontal repetitive transcranial magnetic stimulation in patients with depression, a placebo-controlled crossover trial*. Am. J. Psychiatry 1997, 154: 1752-1756.
35. George MS, Wassermann EM, Williams WA, Callahan A, Ketter TA, Basser P, et al.: *Daily repetitive transcranial magnetic stimulation (rTMS) improves mood in depression*. NeuroReport 1995, 6: 1853-1856.
36. Pascual-Leone A, Rubio B, Pallardo F, Catala MD: *Rapid-rate transcranial magnetic stimulation of the left dorsolateral prefrontal cortex in drug-resistant depression*. Lancet 1996, 347: 233-237.
37. Counter SA: *Neurobiological effects of extensive transcranial stimulation in an animal model*. EEG Clin. Neurophysiol. 1993, 78: 341-348.
38. Matsumiya Y, Yamamoto T, Yarita M, Miyauchi S, Kling JW: *Effect of pulsed magnetic stimulation of the head II, Neuropathological changes in the rat*. J. Clin. Neurophysiol. 1989, 6: 345.
39. Matsumiya Y, Yamamoto T, Yarita M, Miyauchi S, Kling JW: *Physical and physiological specification of magnetic pulse stimuli that produce cortical damage in rats*. J. Clin. Neurophysiol. 1992, 9: 278-287.
40. Ravnborg M, Knudsen GM, Blinkenberg M: *No effects of pulsed magnetic stimulation on the blood-brain barrier in rats*. Neuroscience 1990, 38: 277-280.
41. Sgro JA, Ghatak NR, Stanton PC, Emerson RG, Blair R: *Repetitive high magnetic field stimulation, the effect upon rat brain*. In: Levy WJ, Cracco RQ, Barker AT, Rotwell J (ed.): *Magnetic motor stimulation, basic principles and clinical experience*. Elsevier Science Publishers. Amsterdam. EEG Clin. Neurol. 1991, Suppl. 43: 180-185.
42. Sgro JA, Stanton PC, Emerson RG, Ghatak NR: *Repetitive high magnetic field stimulation, the effect on rat brain*. EEG Clin. Neurol. 1991, 79: 24P.
43. Prato FS, Wills JM, Roger J, Frappier H, Drost DJ, Lee TY: *Blood-brain barrier permeability*

in rats is altered by exposure to magnetic fields associated with magnetic resonance imaging at 1.5 T. Microscopy Res. Tech. 1994, 27: 528-534.

44. O'Callaghan JP, Jensen KF: *Enhances expression of glial fibrillary acidic protein and the cupric silver degeneration reaction can be used as sensitive and early indicators of neurotoxicity.* NeuroToxicology 1992, 13: 113-122.
45. Garcia JH, Yoshida Y, Chen H, Li Y, Zhang ZG, Lian J, et al.: *Progression from ischemic injury to infarct following middle cerebral artery occlusion in the rat.* Am. J. Pathol. 1993, 142: 623-635.
46. Steward O: *Electroconvulsive seizures upregulate astroglial gene expression selectively in the dentate gyrus.* Mol. Brain. Res. 1994, 25: 217-224.
47. Fujiki M, Steward O: *High frequency transcranial magnetic stimulation mimics the effects of ECS in upregulating astroglial gene expression in the murine CNS.* Brain Res. Mol. Brain Res. 1997, 44: 301-308.
48. Chan P, Eng LF, Lee YL, Lin VW: *Effects of pulsed magnetic stimulation of GFAP levels in cultured astrocytes.* J. Neurosci. Res. 1999, 55: 238-244.
49. Wu VW, Schwartz JP: *Cell culture models for reactive gliosis, new perspectives.* J. Neurosci. Res. 1998, 51: 675-681.
50. Walz W, Klimaszewski A, Paterson IA: *Glial swelling in ischemia, a hypothesis.* Dev. Neurosci. 1993, 15: 216-225.
51. Śmiałek M, Gajkowska B, Otrębska D: *Electron microscopy studies on the neurotoxic effect of sodium tellurite in the central nervous system of the adult rat.* J. Brain. Res. 1994, 35: 223-232.
52. Waxman SG, Black JA, Ransom BR, Stys PK: *Anoxic injury of rat optic nerve, Ultrastructural evidence for coupling between Na(+) influx and Ca(2+)-mediated injury in myelinated CNS axons.* Brain Res. 1994, 644: 197-204.
53. Takeyama N, Matsuo N, Tanaka T: *Oxidative damage to mitochondria is mediated by the Ca(2+)-dependent inner-membrane permeability transition.* Biochem. J. 1993, 294: 719-725.

Author's address:

Department of Psychiatry
Collegium Medicum of Jagellonian University
Kopernika 21a St.
31-501 Kraków
Poland

